

# Subacute Sclerosing Panencephalitis Presenting with Unilateral Periodic Myoclonic Jerks

Zaitoon M. Shivji, Ibrahim S. Al-Zahrani, Yousef A. Al-Said,  
Mohammed M.S. Jan

**ABSTRACT: Background:** Subacute sclerosing panencephalitis (SSPE) is a rare complication of measles virus infection. The disease is characterized by behavioural abnormalities, intellectual deterioration, motor weakness, and generalized myoclonic jerks progressing to coma and death in one to two years in 80% of the cases. The myoclonic jerks are associated with characteristic generalized slow periodic complexes on electroencephalography (EEG). The symptoms and signs of SSPE are frequently quite variable. The clinical course is equally variable and difficult to predict. The characteristic periodic myoclonus can rarely occur unilaterally particularly in the early stages of the disease. As well, the periodic EEG complexes have been reported unilaterally in up to 3% of cases. **Case Report:** A 12-year-old boy, who was seen at a later stage with atypical manifestation of myoclonic body jerks confined entirely unilaterally, combined with contralateral periodic EEG complexes. One could assume clinically that the more diseased hemisphere was responsible for generating the jerks. However, brain magnetic resonance imaging revealed asymmetric hemispheric changes suggesting that the less neurologically damaged hemisphere is responsible for generating the unilateral myoclonic jerks. This has led to the interpretation that the more severely damaged hemisphere has lost the neuronal connectivity required to generate these periodic myoclonic jerks. **Conclusions:** Subacute sclerosing panencephalitis may have asymmetric hemispheric involvement, not only early, but also in the advanced stages of the disease, which can result in unilateral periodic myoclonic jerks.

**RÉSUMÉ: Secousses myocloniques périodiques unilatérales comme mode de présentation d'une panencéphalite sclérosante subaiguë.**

**Introduction:** La panencéphalite sclérosante subaiguë (PESS) est une complication rare de l'infection par le virus de la rougeole. La maladie se caractérise par des anomalies du comportement, une détérioration intellectuelle, de la faiblesse musculaire et des secousses myocloniques généralisées progressant vers le coma et la mort en un ou deux ans chez 80% des cas. Les secousses myocloniques sont associées à des complexes périodiques lents généralisés à l'électroencéphalographie (ÉEG). Les symptômes et les signes de la PESS sont souvent variables. L'évolution clinique est également variable et difficile à prédire. Le myoclonus périodique caractéristique peut être unilatérale dans de rares cas, particulièrement dans les phases précoces de la maladie. Des complexes périodiques unilatéraux à l'ÉEG ont également été rapportés chez environ 3% des cas. **Observation:** Il s'agit d'un garçon de 12 ans chez qui on a observé des manifestations atypiques à un stade avancé de la maladie, soit des secousses myocloniques exclusivement unilatérales associées à des complexes périodiques contralatéraux à l'ÉEG. On pourrait présumer selon la clinique que l'hémisphère le plus touché était responsable des secousses. Cependant, l'IRM du cerveau a montré des changements hémisphériques asymétriques suggérant que l'hémisphère moins atteint était responsable des secousses myocloniques unilatérales, ce qui a donné lieu à l'interprétation suivante: l'hémisphère le plus sévèrement atteint a perdu la connectivité neuronale nécessaire pour générer ces secousses myocloniques périodiques. **Conclusions:** Il peut exister une atteinte hémisphérique asymétrique dans la panencéphalite sclérosante subaiguë en phase précoce de la maladie, mais aussi dans les phases avancées, ce qui peut donner lieu à des secousses myocloniques périodiques unilatérales.

Can. J. Neurol. Sci. 2003; 30: 384-387

Viral encephalitis is a rare complication of measles infection.<sup>1</sup> It occurs in one of three distinct types; 1) postinfectious or autoimmune encephalomyelitis, which presents as a sudden recurrence of fever with an altered level of consciousness, seizure activity, and multifocal neurological signs, 2) subacute measles encephalitis (SME; also called subacute inclusion body encephalopathy and progressive infections measles encephalitis) occurring in immunosuppressed patients 1-10 months after measles infection, and 3) subacute sclerosing panencephalitis (SSPE), which presents after six or more years from an acute measles infection with the onset of neurological dysfunction

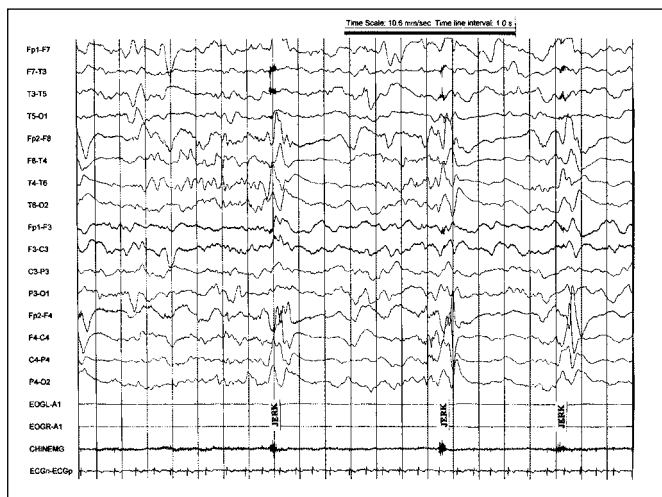
associated with myoclonus and seizure activity. The pathogenesis of SSPE and SME has been attributed to the persistence of measles virus in the central nervous system.

Dawson first described the clinical picture of SSPE in 1933.<sup>2</sup>

From the Department of Neurosciences, King Faisal Specialist Hospital and Research Centre, Jeddah, Kingdom of Saudi Arabia.

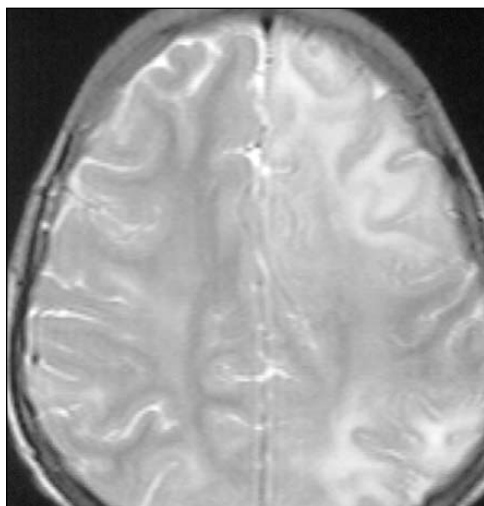
RECEIVED JANUARY 15, 2003. ACCEPTED IN FINAL FORM APRIL 21, 2003.

Reprint requests to: Mohammed M.S. Jan, Paediatric Neurology, Department of Neurosciences, King Faisal Specialist Hospital and Research Center, MBC J-76, PO Box 40047, Jeddah 21499, Kingdom of Saudi Arabia



**Figure 1:** EEG showing slow periodic complexes with maximum voltage over the right hemisphere and synchronized with the left sided body jerks

It was initially believed to be a variant of “encephalitis lethargica”. However, subsequent descriptions of “nodular panencephalitis” and “subacute sclerosing leukoencephalitis” were considered by Greenfield to represent the same clinical entity. He proposed the name “subacute sclerosing panencephalitis”.<sup>3</sup> The disease is characterized by seizures, altered level of consciousness, and multiple neurological deficits including weakness, ataxia, disturbance of language and visual impairment. Those contracting the disease in early childhood usually present with behavioural abnormalities, intellectual deterioration, motor weakness, and generalized myoclonic jerks progressing to coma and death in one to two years in 80% of the cases and most of the remaining patients are dead within 10



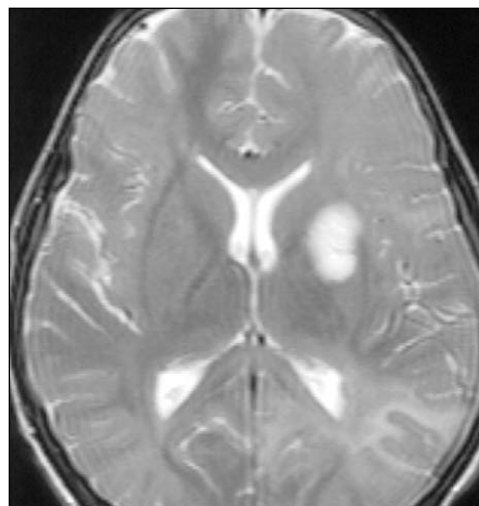
**Figure 2:** Axial T2 weighted brain MRI showing significant white and gray matter involvement with bilateral hyperintense signals maximally involving the left hemisphere

years.<sup>4</sup> The myoclonic jerks are associated with characteristic generalized slow periodic complexes on electroencephalography (EEG).<sup>5</sup> We describe a case seen at a later stage with atypical manifestation of unilateral myoclonic body jerks associated with contralateral periodic complexes on EEG. Brain magnetic resonance imaging (MRI) revealed asymmetric hemispheric changes suggesting that the less neurologically damaged hemisphere is responsible for generating the contralateral myoclonic jerks.

#### CASE SUMMARY

This 12-year-old boy had been healthy up until about seven months prior to presentation. His presenting complaint was that of increasingly frequent falls secondary to bilateral myoclonic jerks of the arms and legs. He had at least two generalized tonic clonic seizures and was treated with valproic acid. His symptoms progressed to involve weakness of both arms and legs with evidence of poor school performance, characterized by inattention, mood liability, speech difficulty, and general cognitive impairment. Before the onset of his symptoms, he had no history of acute or chronic illness, fever, or head injury. He had a viral illness with skin rash and conjunctivitis, which was diagnosed as measles at eight months of age. There was no family history of a similar disorder, mental retardation, or neurodegenerative disease. The parents are first cousins. The initial EEG showed very high amplitude, symmetrical generalized slow periodic complexes correlating with the bilateral myoclonic jerks. The MRI revealed two small hyperintense patches on the T2-weighted images in the deep and periventricular white matter of the occipital regions bilaterally, maximal on the left side.

Six months later, he was referred to our hospital, King Faisal Specialist Hospital & Research Centre (KFSH&RC) in Jeddah for establishing the diagnosis, assessment of his prognosis and the planning of his management. He presented initially in a semi-comatose state after status epilepticus. On examination, the vital signs were normal. He was



**Figure 3:** Axial T2 weighted brain MRI showing the maximum involvement over the left hemisphere, particularly the occipital lobe and basal ganglia

thin, with loss of muscle bulk, and his weight was 24 kg. His head circumference was on the 10th percentile. He was poorly responsive, disoriented, mute, and incontinent.

He required feeding through a nasogastric tube. When aroused he had frequent myoclonic jerks mainly involving the left side of the body (face, arm, and leg). Oculo-cephalic reflexes were present, but gag and cough reflexes were very weak. His pupils were 3-4 mm, equal and reactive to light and his fundal examination was unremarkable. The muscle tone was increased bilaterally with 2-3 muscle power. He had exaggerated reflexes bilaterally with sustained clonus and positive Babinski reflexes.

Cerebrospinal fluid examination revealed normal glucose 4 mmol/L (normal 2.2-4), protein 375 mg/L, (normal 150-450), with 19 RBC, 11 WBC (96% lymphocytes), and no organisms. Cerebrospinal fluid measles IgG was very high at 296 units. Serum measles IgG was also positive at 10.8 units. Blood and urine cultures, as well as malaria and brucella testing, were negative. A detailed metabolic workup was negative. A 21 channel digital EEG using the International 10-20 system of electrode placement was performed at the bedside. Additional electrodes were placed to monitor the eye movements (EOG) and electrocardiogram (ECG). Two electrodes were placed on the left thigh to monitor the surface electromyogram (EMG). The EEG revealed suppression of the background activity with frequent bilateral paroxysmal semi-periodic, very high voltage, broad sharp and slow wave complexes lasting 1-2 seconds and recurring every 4-7 seconds, but clearly more marked and of higher amplitude over the right hemisphere and synchronized with the left sided myoclonic jerks (Figure 1). During light sleep the jerks and movements were present but to a lesser extent. The EEG during sleep still showed some semi-periodic discharges and the asymmetry of amplitude was exaggerated. The suppression of the background electrical cortical activity was maximal over the left hemisphere. The seizures were controlled with valproic acid and clonazepam. A repeat EEG six days later showed similar findings. Brain MRI showed significant white and gray matter disease with bilateral hyperintense signals (on T2), maximum in the left hemisphere where it was diffuse and included the basal ganglia (Figures 2 and 3). The child was placed on oral isoprinosine and supportive care. He unfortunately continued to deteriorate and died four months later at a regional hospital.

## DISCUSSION

The symptoms and signs of SSPE are frequently quite variable.<sup>6</sup> The clinical course is equally variable and difficult to predict.<sup>6,7</sup> Early in the clinical course, SSPE may be difficult to distinguish from psychiatric illnesses such as adolescent adjustment reactions characterized by behavioural and intellectual changes. Unilateral motor deficits are well-described.<sup>8</sup> In the second stage, a prominent feature of SSPE is the stereotyped myoclonic jerks or spasms.<sup>5</sup> The movements are not typically myoclonic in nature (lightening quick jerks) but shock-like abruptness followed by momentary arrest of movement and then a gradual melting to the position of rest. These abnormal movements are seen with the periodic complexes in the EEG. However, particularly in the early stages of the disease, the periodic complexes may be present without the associated motor movements.<sup>9,10</sup> The characteristic periodic myoclonus has been reported unilaterally, particularly in the early stages of the disease.<sup>11,12</sup>

The EEG complexes consist of high voltage (300-1500  $\mu$ V) polyphasic sharp and slow wave complexes lasting 0.5 to 3 seconds in duration and recurring in a periodic fashion every 3 to 12 seconds.<sup>5</sup> These periodic complexes are constant and stereotyped in a single recording but may vary from patient to patient, or within the same patient at different stages of the disease. They are characteristically generalized. However, in a review of 100 cases, unilateral periodic activity was noted initially in three cases.<sup>13</sup> Other authors also recognized EEG variants of bilateral but asymmetric complexes or unilateral complexes.<sup>11</sup> Amplitude asymmetry of the periodic complexes was not uncommon, occurring in 12 out of 67 patients in one series.<sup>14</sup> Other atypical EEG findings have been reported rarely in SSPE including focal epileptiform discharges.<sup>15</sup>

Neuroimaging studies are often abnormal throughout the clinical course of SSPE.<sup>10</sup> Radiographic abnormalities usually correlate with the clinical stage of disease. Magnetic resonance imaging may demonstrate white matter lesions as early as four months after the appearance of the first symptoms of SSPE. In our case, the early MRI changes involved the occipital lobes. Using successive MRI, Sobczyk et al<sup>7</sup> described successive phases of the disease associated with hyperintense changes on T2-weighted images that were situated initially in the occipital lobes, but then went on to involve periventricular white matter and finally the whole of the white matter of both cerebral hemispheres.

Our case combines unilateral periodic EEG complexes and contralateral myoclonus, which is most unusual. Only one previously similar case was described by Ghanem in 1981.<sup>16</sup> In our case the unilateral presentation was rather late in the course and was associated with asymmetric brain involvement on the MRI. Interestingly, the less involved hemisphere on MRI was responsible for producing the unilateral myoclonic jerks. One could assume clinically that in the initial instance the more diseased hemisphere was perhaps responsible for asymmetrically generating the jerks. However, as the disease progressed, the more severely involved hemisphere gradually lost the neuronal connectivity required to generate these periodic myoclonic jerks. We conclude that SSPE may have asymmetric hemispheric involvement not only early, but also in the advanced stages of the disease which may result in unilateral neurological manifestations including unilateral periodic myoclonic jerks.

## REFERENCES

1. Johnson RT, Griffin DE, Hirsch RL, et al. Measles encephalomyelitis – clinical and immunologic studies. *New Eng J Med* 1984;310: 137-141.
2. Dawson JR. Cellular inclusions in cerebral lesions in lethargic encephalitis. *Am J Pathol* 1933;9:7-15.
3. Greenfield JG. Encephalitis and encephalomyelitis in England and Wales during the last decade. *Brain* 1950;73:141-166.
4. Zilber N, Kahana E. Environmental risk factors for subacute sclerosing panencephalitis (SSPE). *Acta Neurol Scand* 1998; 98(1):49-54.
5. Cobb W. The periodic events of subacute sclerosing leuko-encephalitis. *Electroencephalogr Clin Neurophysiol* 1966;21: 278-294.
6. Risk WS, Haddad FS. The variable natural history of subacute sclerosing panencephalitis: a study of 118 cases from the Middle East. *Arch Neurol* 1979; 36(10):610-614.
7. Sobczyk W, Kulczycki J. Sequence of clinical changes and

- evolution of MR images in a case of chronic SSPE. *Neurol Neurochir Pol* 1999;33(5):1165-1172.
8. Dimova P, Bojinova V. Subacute sclerosing panencephalitis with atypical onset: clinical, computed tomographic, and magnetic resonance imaging correlation. *J Child Neurol* 2000;15(4):258-260.
  9. Markland CN, Panszi JG. The electroencephalogram in subacute sclerosing panencephalitis. *Arch Neurol* 1975;32:719-726.
  10. Bohlega S, Al-Kawi MX. Subacute sclerosing panencephalitis: imaging and clinical correlation. *J Neuroimaging* 1994;4:71-76.
  11. Bonifas-Galup P, Hamano K, Sebrosa CJ, Plouin P. Different clinical and electroencephalographic aspects of subacute sclerosing panencephalitis (SSPE). Apropos of 51 cases. *Rev Electroencephalogr Neurophysiol Clin* 1983;13(3):224-231.
  12. Silva DF, Lima MM, Anghinah R, Zanoteli E, Lima JG. Atypical clinical and electroencephalographic pattern in a patient with subacute sclerosing panencephalitis. *Arq Neuropsiquiatr* 1995;53(2):278-280.
  13. Brimani DJ, Sabeti AA, Ghaffar-Pour M, et al. Atypical aspects of the electroencephalogram in subacute sclerosing panencephalitis. *Neurophysiol Clin* 1990;20(2):95-103.
  14. Gurses C, Ozturk A, Baykan B, et al. Correlation between clinical stages and EEG findings of subacute sclerosing panencephalitis. *Clin Electroencephalogr* 2000;31(4):201-206.
  15. Dogulu CF, Ciger A, Saygi S, Renda Y, Yalaz K. Atypical EEG findings in subacute sclerosing panencephalitis. *Clin Electroencephalogr* 1995;26(4):193-199.
  16. Ghanem Q. Unilateral subacute sclerosing panencephalitis complexes with contralateral myoclonus. *Acta Neurol Scand* 1981;63(1):76-80.