

## Clinical note

### Vascular complications following intravascular self-injection of addictive drugs

I. A. AL ZAHRANI,

*Vascular Surgery Unit, Al Noor Specialist Hospital and King Abdulaziz University Hospital, Jeddah, Saudi Arabia*

Drug abuse is a global social and health problem. It seems that all countries are affected including conservative and stable countries like Saudi Arabia. In 1994, 579 new cases of drug and alcohol addiction were reported in Saudi Arabia, which represented 1.1% of all the new psychiatric cases. There was a 30% increase in the numbers of drug users compared with the 1993 statistics.<sup>1</sup> Certainly, the magnitude of the problem has already been noticed in other countries.<sup>2-4</sup> In the United States, the state of Michigan alone, for example, had an estimated 50 000 intravenous heroin users in 1988.<sup>5</sup>

Modern addicts are quite sophisticated with regard to intravenous access sites. However, this is not the case in developing countries where they prepare and inject these substances in a primitive way. In Saudi Arabia, heroin addicts dissolve approximately 1g of heroin in 100 mL tap water, boil the mixture, filter it, then inject themselves in any accessible vessel. Some heroin addicts require more than 10 g/day. This repeated septic vascular access results in serious life and limb-threatening complications. The adverse socio-economic consequences of this self-abuse are not only reflected on the addicts themselves, but also extend to involve each member of their families, particularly when the addict loses one of their limbs. In this article, the first series of patients with vascular complications of drug abuse in Saudi Arabia is reported. The best surgical approaches will be discussed.

## PATIENTS AND METHODS

Between August 1994 and October 1995, 27 patients with vascular complications following intravascular self-injection of heroin were managed in Al Noor Specialist Hospital, all of whom were male. The age range was 25-45 years (mean = 31 years). Among the 27 patients seen, 15 (55.5%) patients presented with a mycotic false aneurysm. Most of the aneurysms involved the common femoral artery ( $n = 11$ ), the rest affected the brachial artery in the antecubital region. Three other patients (11.1%) presented with acutely ischaemic limbs. The remaining nine (33.3%) patients had evidence of iliofemoral deep venous thrombosis (Table 1).

All of the 15 patients with infected false aneurysms presented acutely. Apart from four patients who underwent arteriography (three femoral, one brachial) all of the other patients were taken directly to the operating theatre for further management. In one patient, there was extensive induration of the groin obscuring the pulsating nature of the haematoma. Pre-operative arteriography

Table 1 The clinical presentation of the 27 patients included in the study

Presentation	No.	%
Exsanguinating haemorrhage	5	18.5
Oozing pulsating mass	3	11.1
Infected pulsating mass	5	18.5
Incised groin abscess followed by arterial bleeding	2	7.4
Upper limb ischaemia	2	7.4
Lower limb ischaemia	1	3.8
Iliofemoral deep vein thrombosis	9	33.3
Total	27	100

was necessary in three patients to establish the clinical diagnosis, which had a high index of suspicion (Figure 1). Patients with ruptured femoral artery aneurysms were operated upon urgently in order to control life-threatening haemorrhage and to preserve arterial flow to the affected limb. The standard approach in this department is to start the operation by exposure of the external iliac artery through an extraperitoneal approach, as a preliminary to an extra-anatomical bypass with ringed PTFE. The popliteal artery above the knee is then exposed via a medial incision. During the vascular exposures, the groin aneurysm is compressed if required, by an assistant until the external iliac and the popliteal arteries are cross-clamped. A PTFE 8-mm ringed graft is 'tunnelled' below the fascia of the anterolateral aspect of the thigh to emerge between the sartorius and the vastus medialis at the level of the

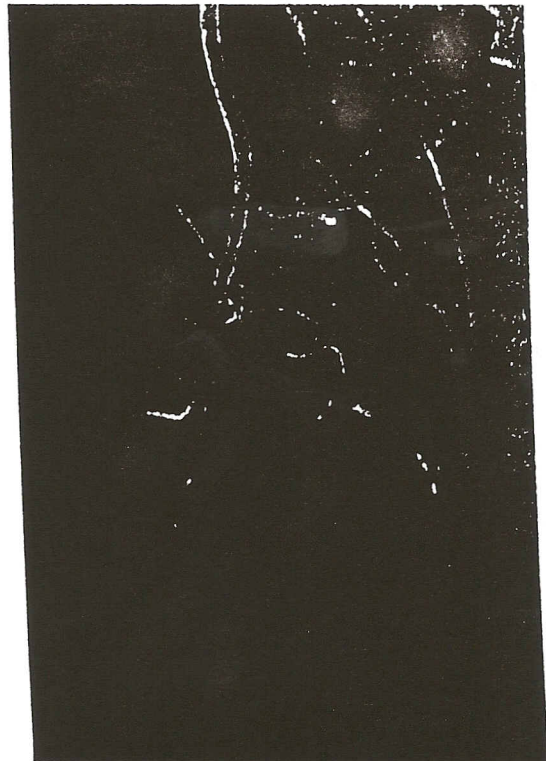

Figure 1 A pre-operative arteriogram of one of addicts showing a false groin aneurysm originating from common femoral artery.

Correspondence: Dr Hasan Ali Al Zahrani, Associate Professor and Consultant Vascular Surgeon, Department of Surgery, King Abdulaziz University Hospital, PO Box 6615, Jeddah 21452, Saudi Arabia.

## 2 Clinical note

adductor hiatus. The proximal and distal anastomosis are then completed and, after ligation of the external iliac artery distal to the proximal anastomoses, the circulation to the lower limb is restored and the operative wounds are dressed with adhesive dressing. The groin aneurysm is then dealt with. The clot and debris within the sac are removed and the common femoral, profunda, superficial femoral and medial circumflex femoral arteries are all ligated, when the common femoral artery is involved or if necessary (Figure 2). After drainage of the abscess and control of bleeding, the aneurysm sac is debrided and left open to heal by secondary intention. In three other patients alternative procedures were performed, namely obturator canal bypass in one case and reversed saphenous vein graft inserted within the aneurysm sac in two

For brachial aneurysms reversed saphenous vein graft was used to revascularize the upper limb in three patients while a vein patch was sufficient in the fourth patient. Pre-operative angiography was necessary in only one case (Figure 3).

Three patients presented with ischaemic manifestations. Below elbow amputation was required in one patient because of neglected irreversible upper extremity ischaemia with a line of demarcation distal to the crease of elbow. In the other patient with hand ischaemia and intact radial and ulnar pulses, intravenous thrombolytic therapy was administered for 48 h followed by anticoagulation. The last patient had foot ischaemia with intact pedal pulses, and was therefore treated conservatively. Nine patients had clinical suspicion of deep venous thrombosis which was confirmed by Duplex scanning and were managed conservatively with antibiotics, intravenous heparin followed by oral anticoagulants.

## RESULTS

In the infected false groin aneurysms group ( $n=11$ ), one patient with ruptured femoral aneurysm died in the emergency room before operation because of exsanguinating haemorrhage. Control of bleeding and immediate revascularization of the lower limb were achieved successfully in the remaining 10 patients. The early and

Table 2 Early and late postoperative complications in the infected groin aneurysm ( $n=10$ )

Procedure	Complication	Outcome
Early ( $n=3$ )		
Vein graft	Bleeding	Controlled
Vein graft	Thrombosis	Viable limb
PTFE iliopop	Pulmonary embolism	Expired
Late ( $n=2$ )		
PTFE Obturator	Thrombosis	Viable limb
PTFE Iliopop	Thrombosis	Removal of graft

Early: within 1 month.

Late: 1–12 months.

late post-operative complications are listed in Table 2 for the various procedures. Among the five complicated cases only two were in those who underwent PTFE iliopopliteal bypass ( $n=7$ ) via a lateral route. The remaining five patients who underwent extra-anatomic PTFE iliopopliteal bypass did well. However, one of them had an above knee amputation for a useless infected knee. In the follow-up period two more deaths occurred. One from drug overdose and the other from septicaemia as a result of skin infections. Both were cases of reversed saphenous vein bypass.

Patients with brachial aneurysms had an uneventful post-operative period. They were followed up for 2–8 months and two of them sustained right iliofemoral deep vein thrombosis from self-injection of heroin into the femoral vein.

One patient of the two presenting with acute upper limb ischaemia had a below elbow amputation. He returned 1 year later with a right iliofemoral deep vein thrombosis. One patient with foot ischaemia who improved after conservative treatment was readmitted to hospital 8 months later because of right iliofemoral deep vein thrombosis.

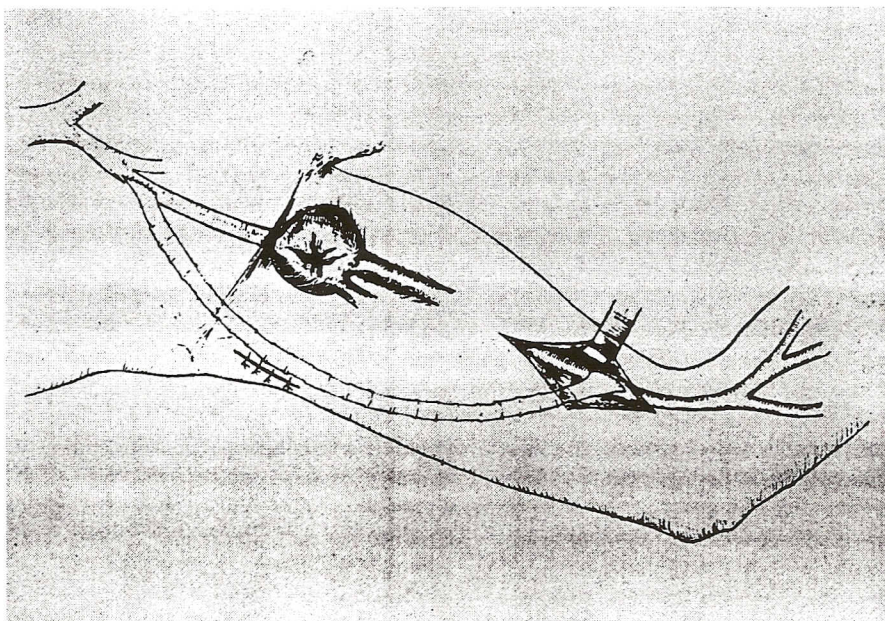


Figure 2 Our procedure of choice. Extra-anatomic (lateral femoral) iliopopliteal bypass using ringed PTFE to revascularize the lower limb after ligation—excision of infected groin pseudoaneurysm

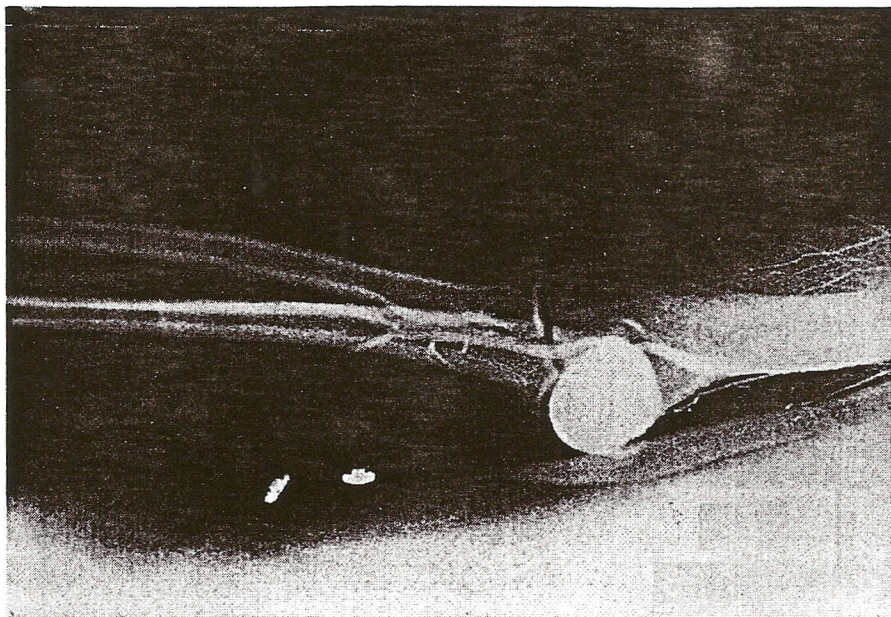


Figure 3 A pre-operative arteriogram of a brachial pseudo-aneurysm in a drug addict.

All the nine patients with iliofemoral deep vein thrombosis had an uncomplicated hospital stay. None of them had evidence of pulmonary embolism or chronic venous insufficiency during a 2 to 12 month follow up period.

## DISCUSSION

Increasing number of patients who indulge in substance abuse seem dedicated to destroying themselves in graduated steps. The peak of this sad ongoing practice is encountered when they start injecting into major veins 'cold blood vessel' and/or arteries 'hot blood vessel' in order to experience the thrilling high effect. These practices of mainlining in a major vessel are almost always associated with a lack of precise anatomical knowledge and use of contaminated needles leading to a variety of major vascular complications including the formation of infected pseudo-aneurysms, distal ischaemia, septic and non-septic phlebothrombosis or thrombophlebitis.

Similar to other reports,<sup>5-6</sup> young males predominated in our series, and none of our patients was female. Early diagnosis depends on a high index of suspicion and the awareness that some of these patients hide their habit particularly in conservative societies. Two of the infected false groin aneurysms were incised by general surgeons on the assumption that they were 'groin abscesses'. One of the patients died from exsanguinating haemorrhage during transportation to our unit. Similar mishaps were cited in the literature.<sup>7</sup> Berguer and Benitez<sup>8</sup> described the pus, blood and a pulsatile groin mass as an unforgettable triad. In view of this, most cases are diagnosed clinically. In contrast to Reddy *et al.*<sup>5</sup> who advocated routine arteriography, we believe that the time lost in angiography suits as well as the injection pressure represent a real risk in rupturing these pseudo-aneurysms and indicate a selective use of this technique.

Similarly, ultrasonography is of very limited value diagnostically and for further management.<sup>3</sup> Sandler *et al.*<sup>9</sup> detected only one femoral pseudo-aneurysm among sonograms of 72 patients with pain and swelling of the groin caused by intravenous drug abuse.

Duplex scanning was used to confirm the diagnosis of deep venous thrombosis but was never attempted in diagnosing pseudo-aneurysms cases.

The optimum surgical management of the infected groin pseudo-aneurysm is still controversial particularly with regard to immediate revascularization.<sup>6,8,10</sup> We adopted a plan of predetermined use of a remote iliopopliteal bypass via a lateral femoral route using an externally supported PTFE graft followed by ligation—excision and extensive debridement of the false aneurysm leaving it to heal by secondary intention. Our justification for this aggressive approach was based on the fact that with current advances both in the antibiotics industry and in vascular surgery, all major vessels should be reconstructed whenever possible. Most of the affected patients are young males who need, in addition to psychiatric treatment, an active social and occupational rehabilitation programme to help them to end this serious habit. This goal may not be achieved if the patient is confined to their home because of incapacitating intermittent claudication in the non-revascularized group. We believe that the relative limited probability of graft infection does not justify leaving these patients to face the sequelae of conservative approaches described in the literature, i.e. limb loss or severe claudication.<sup>6,10</sup>

Alternative procedures were used in three patients (two cases of reversed saphenous vein grafts and one case of obturator canal bypass). Unlike other authors<sup>1</sup> we were not impressed with the results of using the vein as a conduit, as one of the two patients had secondary haemorrhage due to infection of the vein graft and the other thrombosed. Certainly, the saphenous vein graft is at a great risk of thrombosis or of disintegration in such an infected area. Obturator canal bypass is not a reliable alternative to our standard procedure as the graft occluded in 3 months time.

Brachial aneurysms were easily diagnosed, controlled and treated. The outcome, as far as life and limb salvage rate are concerned, was satisfactory. Three addicts presented with acute vascular insufficiency and were treated conservatively. The outcome of the management of ischaemic cases depends on the type of drug, the amount injected and the time before treatment.<sup>11</sup> In the patients

in this study talcum powder and starch were used to 'cut' the heroin and parts of these noxious agents have subsequently embolized distally. Treatment with anticoagulation, thrombolytic therapy, prostacyclin and sympathectomy have been reported in the literature.<sup>8,12</sup> All of these measures were used in our series. Nine patients present primarily with iliofemoral deep venous thrombosis. Theoretically speaking, patients with deep venous thrombosis are at a higher risk of septicaemia rather than pulmonary embolism. Nine of the nine cases studied developed such a complication.

The serious nature of intravenous drug abuse cannot be underestimated, it is a very difficult habit to break even with some form of psychiatric management. The patient is thus exposed to a chain of problems and can end up by losing either limb or life. Physicians caring for these patients experience many frustrations of on-going 'battles', however, some satisfaction can be gained when timely surgical care saves limbs and lives. In contrast to reports in the literature, we recommend an aggressive surgical approach aimed at limbs and life salvage followed by an active programme of psychiatric and social rehabilitation. Nevertheless, the long-term prognosis in our experience is poor and unpredictable.

## REFERENCES

- 1 Ministry of Health. New cases of psychiatric disorders by Main Diagnostic Group: Annual Health Report, Statistics Department. MOH, Riyadh 1994; 60.
- 2 National Institute on Drug Abuse (NIDA) : Drug Abuse and Drug Abuse Research. *Second Report to Congress from the Secretary*, Department of Health and Human Resources, Washington, D.C. 1987; 87: 1486.
- 3 Reddy DJ, Beale HR. Vascular injuries from drug abuse. In: Flanigan DP, ed. *Civilian Vascular Trauma*. Pennsylvania : Lea & Febiger, 1992: 295-305.
- 4 Reid DB, Reid AW, Welch GH, Scott RN, Going J, Pollock JG. Arterial damage in intravenous drug addicts in Glasgow. *Saudi Heart* 1993; 1: 57-62.
- 5 Reedy DJ, Smith RF, Elliot Jr, Haddad GH, Wanek EA. Infected femoral artery false aneurysm in drug addicts: evolution of selective vascular reconstruction. *J Vasc Surg* 1986; 3: 718-24.
- 6 Patel KR, Samel L, Clauss RH. Routine revascularization with resection of infected femoral pseudoaneurysm from substance use. *J Vasc Surg* 1988; 8: 321-8.
- 7 Johnson JR, Ledgerwood AM, Lucas CE. Mycotic aneurysm: new concepts in surgery. *Arch Surg* 1983; 118: 577-82.
- 8 Berguer R, Benitez P. Surgical emergencies from intravascular injections of drugs. In: Bergan JJ, Yaw JST (eds) *Vascular Surgical Emergencies*. Orlando Florida, Grune & Stratton, Inc., 1987; 309-16.
- 9 Sandler MA, Alpern MB, Madrazo BL, Gitschlag KF. Inflammatory lesions of the groin: ultrasonic evaluation. *Radiology* 1984; 151: 747-50.
- 10 Reddy DJ. Treatment of drug-related infected false aneurysm of the femoral artery—Is routine revascularization justified? *J Vasc Surg* 1988; 8: 344-5.
- 11 Lindell TD, Porter JM, Langstone C. Intra arterial injection of oral medication: a complication of drug injection. *N Eng J Med* 1972; 30: 1132-33.
- 12 Al Zahrani H. Sympathectomy in treatment of peripheral ischaemia related to intra-arterial drug abuse. *Saudi Heart J* 1993; 4: 75.