

Case Reports

Cerebellar abscess due to *Listeria monocytogenes*

Bassam M. Addas, MBBS, FRCS(C), Mohammed S. Jan, MBCChB, FRCP(C).

ABSTRACT

Brain abscess due to *listeria monocytogenes* mainly involves the cerebral hemispheres. Cerebellar abscess is an infrequent event, which could lead to rapid neurological deterioration if unrecognized. We present a case of multiple brain stem and cerebellar abscesses in a previously healthy individual exposed to unpasteurized milk. This is the 2nd case of cerebellar abscess due to *listeria monocytogenes* reported in the English literature. The diagnosis of *listeria monocytogenes* was made in the surgical specimen. Our case illustrates the difficulty of early diagnosis of cerebellar *listeria monocytogenes* abscesses and the importance of prompt neurosurgical intervention.

Keywords: Cerebellum, abscess, *listeria monocytogenes*, rhomboencephalitis.

Saudi Med J 2002; Vol. 23 (2): 226-228

Listeria monocytogenes (*L.monocytogenes*) is a gram-positive bacillus that has a peculiar predilection for the central nervous system (CNS) causing mainly meningitis, encephalitis and rhomboencephalitis.¹⁻³ Cerebral abscess formation is a rare result of *L.monocytogenes* infection.⁴ Only 14 cases of cerebral abscess formation due to *L.monocytogenes* were found in a review of the literature in this subject.⁵ Cerebellar abscess due to *L.monocytogenes* appears to be even a less frequent event. Only one previous case of cerebellar abscess has been reported in the English literature.⁶ Although *L.monocytogenes* CNS infection is more common in immunosuppressed or debilitated patients, cerebral abscess formation has been described in healthy individuals.⁷⁻⁹ We report a case of a non-immunocompromised man who developed multiple cerebellar and brain stem *L.monocytogenes* abscesses.

Case Report. A 70-year-old man presented with a one-week history of right-sided parietal

headache, photophobia, right facial numbness, double vision, and severe vertigo. His past medical history included a hiatus hernia repair and appendectomy. The patient had a history of regularly ingesting unpasteurized milk. Physical examination revealed an oral temperature of 38.8°C. The neurological examination showed that the patient was alert and oriented. There were decreased sensations on the right side of the face and gait ataxia. The patient was admitted to the hospital with a working diagnosis of viral meningitis. A lumbar puncture was performed and the cerebrospinal fluid (CSF) analysis showed lymphocytic pleocytosis 204 x 10⁶ with 74% monocytosis, high protein of 688mg/dl and normal glucose of 3.8mg/dl. Gram stain and CSF culture were negative. Hematological analysis and blood cultures were also negative. The patient had a brain computerized tomography (CT) scan on admission, which was reported as normal. Fifteen days later, his condition deteriorated and required artificial ventilation. Approximately one week after his initial CT a brain magnetic resonance imaging (MRI) with

From the Department of Surgery, (Addas), King Abdulaziz University Hospital and the Department of Neurosciences, (Jan), King Faisal Specialist Hospital & Research Center, Jeddah, Kingdom of Saudi Arabia.

Received 14th July 2001. Accepted for publication in final form 4th August 2001.

Address correspondence and reprint request to: Dr. Mohammed S. Jan, Department of Neurosciences, King Faisal Specialist Hospital and Research Center, MBC J-76, PO Box 40047, Jeddah 21499, Kingdom of Saudi Arabia. Tel. +966 (1) 6677777 Ext. 5819. Fax. +966 (1) 6677777 Ext. 5813. E-mail: mmsjan@yahoo.ca

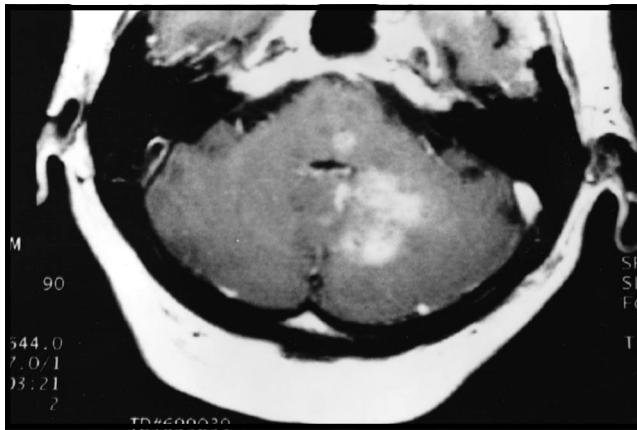

Figure 1 - Magnetic resonance imaging with gadolinium enhancement (Axial T1 weighted) showing multiple ring enhancing lesions in the pons and the left cerebellar hemisphere.

gadolinium enhancement was performed, which showed multiple ring enhancing lesions of the brain stem and the left cerebellar hemisphere (**Figure 1**). The patient was started on broad-spectrum antibiotic coverage (Ceftriaxone, Cloxacillin and Metronidazole). Shortly after, there was neurological deterioration secondary to cerebellar swelling resulting in obstructive hydrocephalus. The patient was treated with an emergency ventriculostomy and subsequently underwent a decompressive suboccipital craniectomy and excision of the cerebellar lesion. The histological examination of the lesion revealed necrotic white matter and prominent fibrinoid necrosis of the parenchymal vessels. Microbiological analysis showed gram-positive rods and cultures of the surgical specimen grew

L.monocytogenes (**Figure 2a & 2b**). Although the patient's condition improved after appropriate intravenous antibiotic therapy was started (Ampicillin), he later required rehabilitation for residual ataxia.

Discussion. The affinity of *L.monocytogenes* to the CNS is well known. Meningitis accounts for about 50% of the CNS infections by *L. monocytogenes*.^{10,11} Parenchymal cerebritis can also occur, but without abscess formation.¹⁰ Cerebral and cerebellar abscesses due to *L.monocytogenes* are extremely rare.⁶ Our case is the 2nd to be reported in the English literature and both cases presented with concomitant brain stem involvement, which included the middle cerebellar peduncle.⁶ Brainstem abscess caused by *L.monocytogenes* has been previously reported and it can be postulated that cerebellar involvement may be secondary to brain stem abscess, spreading via the middle cerebellar peduncle. Abscess formation is believed to be related to hematogenous spread. Positive blood culture is common in patients with *L.monocytogenes* suggesting that the brain is seeded after *L. monocytogenes* bacteremia. Multiple abscesses in the cerebellum and brain stem could lead to rapid neurological deterioration to acute hydrocephalus secondary to compression of the CSF pathways, as in the present case, or increase intracranial pressure within the posterior fossa causing a herniation syndrome. Surgical intervention for decompression of the posterior fossa in patients presenting with mass effect and neurological deterioration secondary to multiple brain stem and cerebellar abscess, suspected to be due to *L.monocytogenes* should be considered

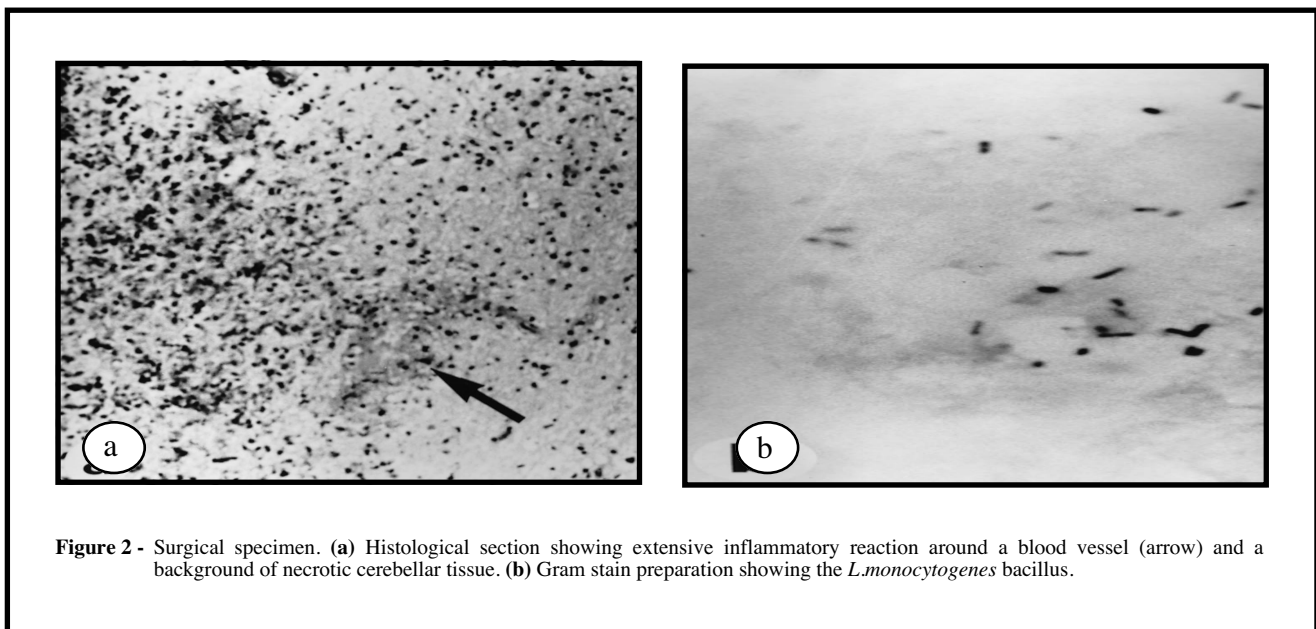


Figure 2 - Surgical specimen. (a) Histological section showing extensive inflammatory reaction around a blood vessel (arrow) and a background of necrotic cerebellar tissue. (b) Gram stain preparation showing the *L.monocytogenes* bacillus.

promptly. It is well known that immunocompromised patients or individuals at the extremes of age are more susceptible to *L.monocytogenes* infection. Listeriosis is one of the most common causes of meningitis in renal and cardiac transplant patients.¹²⁻¹⁴ Other susceptible groups include acquired immune deficiency syndrome patients,⁷ individuals with hematological malignancies,^{15,16} and patients on steroids or cytotoxic chemotherapy.¹⁷ However, brain abscess due to *L.monocytogenes* can occur in healthy individuals. In the present case, there was an exposure to unpasteurized milk, which has been reported as a source of *L.monocytogenes* infection.¹⁸⁻²⁰ Exposure to farm animals and contaminated raw meat have also been considered a source of *L.monocytogenes* infection.^{8,19-21} The clinical picture of *L.monocytogenes* infection of the brain stem (Rhombencephalitis) has a biphasic pattern, presenting initially with headache, vomiting and fever, and lasting for 3-10 days. During this phase, CSF cultures and cranial CT scans are usually negative, often leading to a delay in diagnosis and start of appropriate antimicrobial therapy, as in the present case.^{21,22} The 2nd phase is characterized by signs and symptoms characteristic of brain stem or cerebellar involvement such as ataxia or cranial nerve palsies.^{13,23} The diagnosis of *L.monocytogenes* abscess is based on blood, CSF or tissue gram stain and cultures. In our patient the organism was identified in the surgical specimen obtained from the cerebellum.

To conclude, although brainstem or cerebellar abscess due to *L.monocytogenes* is rare, it should be considered both in immunocompromised and healthy individuals exposed to raw meat or unpasteurized milk. Usually, initial CT scans and CSF cultures are negative. However, if the diagnosis of *L.monocytogenes* is suspected, prompt treatment with appropriate antimicrobial therapy (Ampicillin) should be initiated. Neurological deterioration due to increased intracranial pressure or obstruction of CSF pathways should be treated neurosurgically without delay.

References

1. Mylonakis E, Hohmann EL, Calderwood SB. Central nervous system infection with listeria monocytogenes. 33 years' experience at a general hospital and review of 776 episodes from the literature. *Medicine* 1998; 77: 313-336.
2. Armstrong RW, Fung PC. Brainstem encephalitis (rhombencephalitis) due to listeria monocytogenes: case report and review. *Clin Infect Dis* 1993; 16: 689-702.
3. Lorber B. Listeriosis. *Clin Infect Dis* 1997; 24: 1-9.
4. Samra Y, Hertz M, Altman G. Adult listeriosis - A review of 18 cases. *Post Grad Med J* 1984; 60: 267-269.
5. Kennard C, Howard AJ, Schotz C. Infection of the brainstem by listeria monocytogenes. *J Neurol Neurosurg Psychiatry* 1979; 42: 931-933.
6. Louria DB, Blevins A, Armstrong D. Listeria infections. *Ann NY Acad Sci* 1974; 174: 545-551.
7. Dee RR, Lorber B. Listeriosis, review of the literature. *Rev of Inf Dis* 1986; 8: 968-977.
8. Chernik NL, Armstrong D, Posner JB. Central nervous system infections in patients with cancer. *Medicine* 1973; 52: 563-581.
9. Chernik NL, Armstrong D, Posner JB. Central nervous system infections in patients with cancer: Changing Pattern. *Cancer* 1977; 40: 268-274.
10. Abeysounis CJ. Corynebacterium and listeria. In: Milgrom F, Flanagan TD, editors. *Medical Microbiology*. New York (US): Churchill Livingstone; 1982: p. 375-387.
11. Schuchat A, Robinson K, Wenger JD, Harrison LH, Farley M, Reingold AL et al. Bacterial meningitis in the united states in 1995. Active surveillance team. *N Engl J Med* 1997; 14: 970-976.
12. Hooper DC, Pruitt AA, Rubin RH. Central nervous system infections in chronically immunosuppressed. *Medicine* 1982; 61: 166-188.
13. Hotson JR, Pedley TA. The neurological complication of cardiac transplantation. *Brain* 1976; 99: 673-694.
14. Skogberg K, Syrjanen J, Jahkola M, Renkonen OV, Paavonen J, Ahonen J et al. Clinical presentation and outcome of listeriosis in patients with and without immunosuppressive therapy. *Clin Infect Dis* 1992; 14: 815-821.
15. Douen AG, Bourque PR. Musical Auditory Hallucinations from Listeria Rhombencephalitis. *Can J Neurol Sci* 1997; 24: 70-72.
16. Brernguer J, Solera J. Listeriosis in patients infected with Human Immunodeficiency Virus. *Rev of Infect Diseases* 1991; 13: 115-119.
17. Uldry PA, Kuntzer T, Bogouslavsky ET. Early symptoms and outcome of Listeria monocytogenes rhombencephalitis. 14 adults cases. *J Neurol* 1993; 240: 235-242.
18. Dalton CB, Austin CC, Sobel J, Hayes PS, Bibb WF, Graves LM et al. An outbreak of gastroenteritis and fever due to listeria monocytogenes in milk. *N Engl J Med* 1997; 336: 100-105.
19. Morrison RE, Brown J, Gooding RS. Spinal cord abscess caused by Listeria monocytogenes. *Arch Neurol* 1980; 37: 243-244.
20. Schuchat A, Deaver KA, Wenger JD, Plikaytis BD, Mascola L, Pinner RW et al. Role of foods in sporadic listeriosis. I. Case-control study of dietary risk factors. The listeria study group. *JAMA* 1992; 267: 2041-2045.
21. Wilson GS, Miles AA. Corynebacterium and other non spore-forming gram-positive rods. In: *Principles of Bacteriology, Virology and Immunology*. 6th ed. London (UK): Edward Arnold; 1975. p. 186-187.
22. Heck AF. Infection of the Nervous system Part 1. In: Vinken PJ, Bruyn GW, editors. *Handbook of Clinical Neurology*. Vol. 33, Amsterdam, Holland: North Holland Publishing Company; 1978. p. 80-82.
23. Nieman RE, Lorber B. Listeriosis in adults: a changing pattern. Report of eight cases and review of the literature 1968-1978. *Rev Infect Dis* 1980; 2: 207-227.